**PATIENT**

Julius Badeker

SPECIES

Feline

BREED

DSH

SEX

Male Neutered

AGE

10.1.12

WEIGHT

11lbs

INTERPRETED BYMaggie Machen Lamy,
DVM, DACVIM
(Cardiology)**HOSPITAL NAME**Aberdeen Veterinary
Clinic**REFERRING VET**

Dr. Fritz

INVOICE

30183

DATE

4.11.23

PRESENTING CLINICAL SIGNS

History: Cardiac murmur found on PE for facial mass.

-Current medications: None.

-Sedation used: Not required to complete full diagnostic ultrasound.

-Pertinent previous ultrasound results: No previous.

-STAT: Declined at this time.

-Imaging performed by: Stephanie Warga RDCS, RVT.

ECHOCARDIOGRAM FINDINGS

2D, m-mode, color flow and doppler imaging is available. The left ventricular wall is mildly hypertrophied with regions of irregularity. There is a diffusely hyperechoic endocardium consistent with fibrosis and ventricular remodeling. Papillary muscle hypertrophy. The right ventricle is subjectively normal in size and morphology. Mild to moderate left atrial dimension with a horizontal component; no spontaneous contrast. No right atrial enlargement present. Normal RVOT velocity. There is systolic anterior motion (SAM) of the mitral valve present, with a severely elevated LVOT velocity and a dynamic profile. There is mild mitral regurgitation present secondary to SAM. Trace TR. No obvious additional valvular regurgitation is present. There is no pericardial effusion noted. No pleural effusion appreciated. No obvious cardiac tumors.

CARDIAC CHART

FELINE CARDIAC PARAMETERS	BODY WEIGHT (kg)	HR (BPM)	IVSd (cm) <small>(Moise, Pipers)</small>	LVIDd (cm) <small>(Moise, Pipers)</small>	LWVd (cm) <small>(Moise, Pipers)</small>	FS (%)	EF (%)
NORMAL PARAMETER	-----	150-240	3.5-0.55	<2 (mean 1.5)	3.5-0.55	35-67	80-100
PATIENT	5.0	NM	0.66	1.36	0.65	56	89
FELINE CARDIAC PARAMETERS	LA/AO <small>(Boon)</small>	LA/AO HEART BASE (Swe) <small>(Abbott)</small>	LA 2D short axis Base view (cm) <small>(Abbott)</small>	LVOT VEL (m/s)	RVOT VEL (m/s)	E max (m/s)	
NORMAL	<1.5	<1.3	<1.2	<1.6	<1.3	<0.9	
PATIENT	NM	1.7	1.5	5.0	2.1	NM	

Adapted from June Boon, Veterinary Echocardiography, 1998
 Abbott J & MacLean H JVIM 2006;20: 111-119, Moise et al. Am J Vet Res 47:1476, 1986. Pipers et al. Am J Vet Res 40:882, 1979.

INTERPRETATION OF THE FINDINGS & FURTHER RECOMMENDATIONS

The diagnosis is hypertrophic obstructive cardiomyopathy. This indicates some degree of LV hypertrophy (mild in this case) with a dynamic LVOT obstruction (SAM) and secondary MR. There is mild to moderate left atrial dilation present, indicating the risk of spontaneous CHF and/or a thrombotic event is elevated. There is also a dynamic obstruction through the RVOT, which is a benign finding secondary to tachycardia.

While no medications have been shown to definitively alter long term outcome at this stage of disease, it is reasonable to initiate atenolol at this time as below in light of a tachycardia, significant LVOTO and LA dilation. Plavix is also reasonable given LA dilation; however, this can be difficult to administer. Prognosis is guarded with LA dilation, although there is great variability in rates of progression with subclinical feline cardiomyopathy.

Monitor at home for any respiratory signs or blood clot events (neurologic change, paralysis, etc.) in the future. Anesthetic risk is considered mild, however judicious IV fluid rates are advised to avoid fluid overload. Additionally drugs that stimulate heart rate should be avoided unless clinically necessary (glycopyrrolate, atropine). Avoid vasodilators as this may worsen the obstruction. A reasonable protocol includes opioid/benzodiazepine premedication, propofol induction, and isoflurane maintenance.

Risk for complication with steroid use typically follows LA dilation, which in this case is significantly elevated. Ideally consider an alternative such as Budesonide as a safer choice. If needed for systemic wellness however, monitoring of RR/RE is advised particularly in the initiation phase.

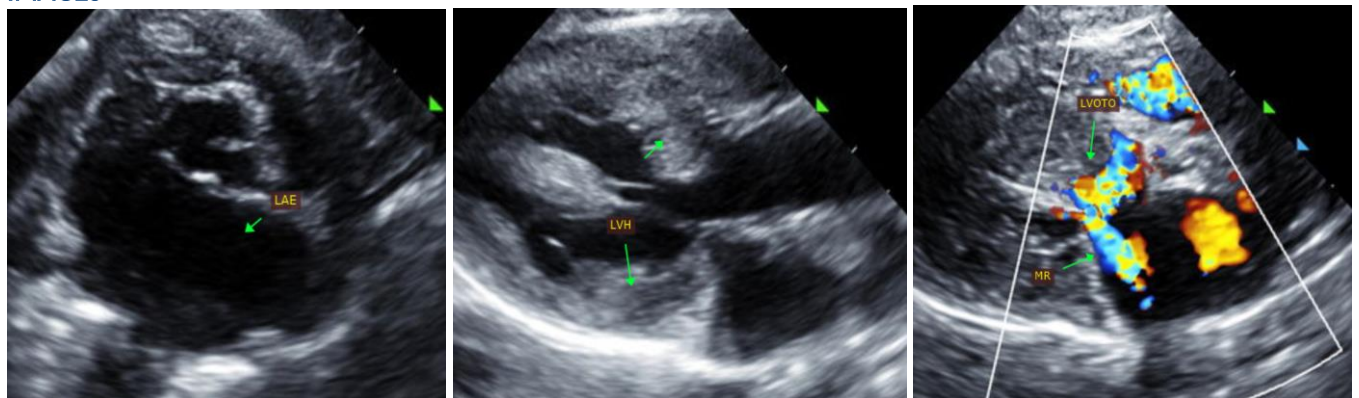
PLAN

Administer titrating dose of atenolol: 25mg tablets; Give ¼ tab once daily. Recheck heart rate in 1-2 weeks with target stressed rate of 140-160bpm 12-24 hours post-administration. Increase as needed until target reached. Consider blood thinner Clopidogrel (Plavix) 75mg tablets; give ¼ tab orally once daily (NOTE: this medication is very bitter on the cut edges).

Screening blood pressure and T4 are recommended every 6 months.

Recommend recheck echocardiogram in 6 months to assess for progression, sooner if clinical issues arise.

IMAGES



The information and recommendations provided are based on the images presented by the referring veterinarian. No evaluation can be communicated regarding pathology that was not visible in the image/video clips provided.

Thank you for this referral. This report was generated using transcription software, and minor dictation errors may be present. If the clinical or image interpretation does not parallel your findings or if I can be of any further assistance please contact me.

Maggie Machen Lamy, DVM
Diplomate of the American College of Veterinary Internal Medicine (Cardiology)
info@sonopath.com